

Victims of the Quake

An almost complete absence of human remains trapped in the destruction level of the Sanctuary argues that effectively nothing in the way of worship or even repairs was taking place at the precise moment that the earthquake struck. Perhaps it came in the night. But at least two witnesses were on hand to experience its terrors and then to pay a terrible price for their presence. This is their story.

The skeletal remains of two very young children were found in a shallow crevice formed when the heavy ashlar capping of the post-A.D. 115 retaining wall (T20) that separates the Middle from the Lower Sanctuary split open under earthquake pressure. When found, the body of the better preserved of the two individuals had fallen on its back with its head pointing west. Wedged into the narrow gap the head was pressed forward so that the chin rested against its chest. The right arm lay parallel to its side, the left was extended over the pelvis (Figs. 3, 4).

How did the tiny victims die? Did they live to see the devastation of the earthquake? Did they become trapped and die of suffocation? Bits and pieces from the skeletons cannot answer such questions with certainty, but other clues are nevertheless revealed in the bones.

The First Child

The outline of the body was quite clear at the time of excavation, beginning at the head with the lower jaw extending towards the chest area and fragments of aligned vertebrae and ribs; arms placed to the sides; a pelvis with lower limb bones in their correct anatomical position stretching parallel to the wall's massive blocks. This individual either died lying on its back or was positioned there face up as if in a grave.

The projecting and fragile elements of the skeleton were all fragmentary and distorted by the pressure of the overburden of soil. Once the skeleton had been brought back to the Physical Anthropology Lab at The University Museum and the glue used to consolidate its remains in the field removed, the fragments could no longer be positioned precisely, relative to one another, because each piece had been pressure-distorted in unique ways. For example, the precise fit between each of the skull's fragments has been lost so that its appearance after reconstruction is lopsided. Similar distortions are also apparent in the thin fragile bones of the pelvis and the scapula (shoulder blade).

Virtually all of the bones of this individual are represented except for the wrist and ankle joints. Why these are absent is a mystery. It is possible that the grave was disturbed by the action of moving water which washed away these small, light skeletal bits. Alternatively, it is possible that they were removed by the small mammals and birds that inhabited the nearby wadi, picking over the Sanctuary after the earthquake.

The Second Child

Analysis in the Museum's lab posed a second and perhaps more interesting unsolvable mystery. Scattered throughout the skeleton just described were the remains of yet another individual. This second victim is represented by bone fragments that either are too small to be part of the first or else duplicate pieces of the skeletal remains already associated with the first. These bones are indeed tissue-thin by comparison with those of the first individual. Since the bones of living individuals not only become larger with age but increase in mass, these must belong to a much younger child.

The second set of remains consists of skull bones, parts of the rib cage, breast bone, and elements of the upper and lower limbs. Ten complete fragile ribs are present. Most peculiarly, however, everything that survives belongs to the right side of the body!

Did this second individual die along with the first? Was the first, larger child carrying the second when the earthquake hit and entrapped them? The excavation data again fail to answer this question.

Age and Sex of the Two Skeletons

Although the sex of an individual is quite easy to assess from an adult skeleton, the same does not apply to the analysis of immature remains. Most sex-related differences in the skeleton are not developed during childhood. For example, the very clear anatomical differences in the pelvis of males and females strongly develop during puberty and are retained into adulthood. With the pelvis of an adult the sex of the individual can be determined with a high degree of accuracy. With children, however, as in the case of the Sanctuary's two individuals, these differences cannot be determined.

On the other hand, the age at death of immature remains is actually easier to gauge than with mature or adult remains. Specifically, the degree of development of the teeth or dentition reflects the developmental level of the child. The pattern for what is called calcification or formation and eruption of the dental tissues has been broadly assessed in many human populations. Applied to the older Sanctuary victim, our analysis indicates that he or she died between the ages of three to three-and-a-half years old (and had suffered from prematurely worn teeth).

The skeleton of the second individual most certainly is that of a term or near-term infant. Since a three year-old is probably too young to have carried even a newborn infant, we must imagine that the tiny infant was accompanied by a third, older child or adult. The soil directly south of the two bodies beneath the excavation's Decauville railroad tracks still lies unexplored, which makes it possible that our missing "third man" lies buried under the rails, or perhaps he or she somehow escaped alive.

Janet Monge

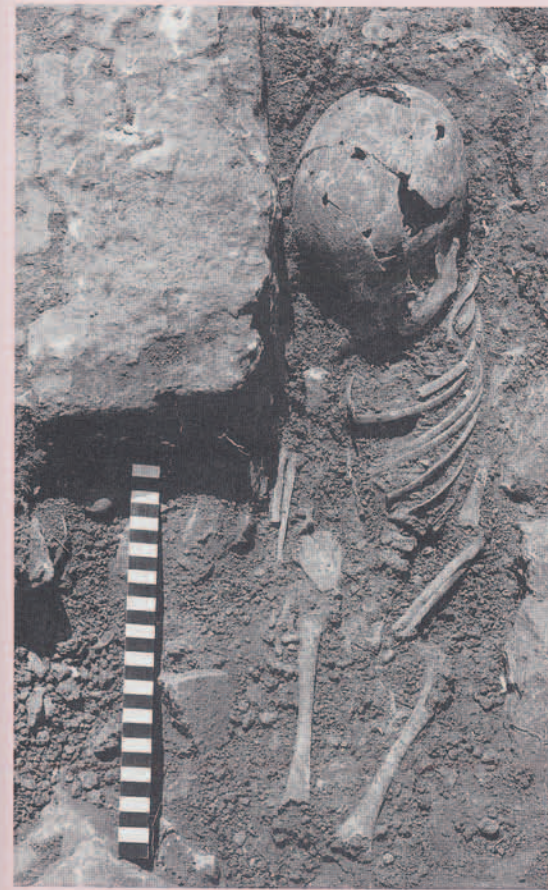

Figure 3. Skeletal remains of the child found trapped in earthquake debris in a cleft in the retaining wall (T20) separating the Lower from the Middle Sanctuary.

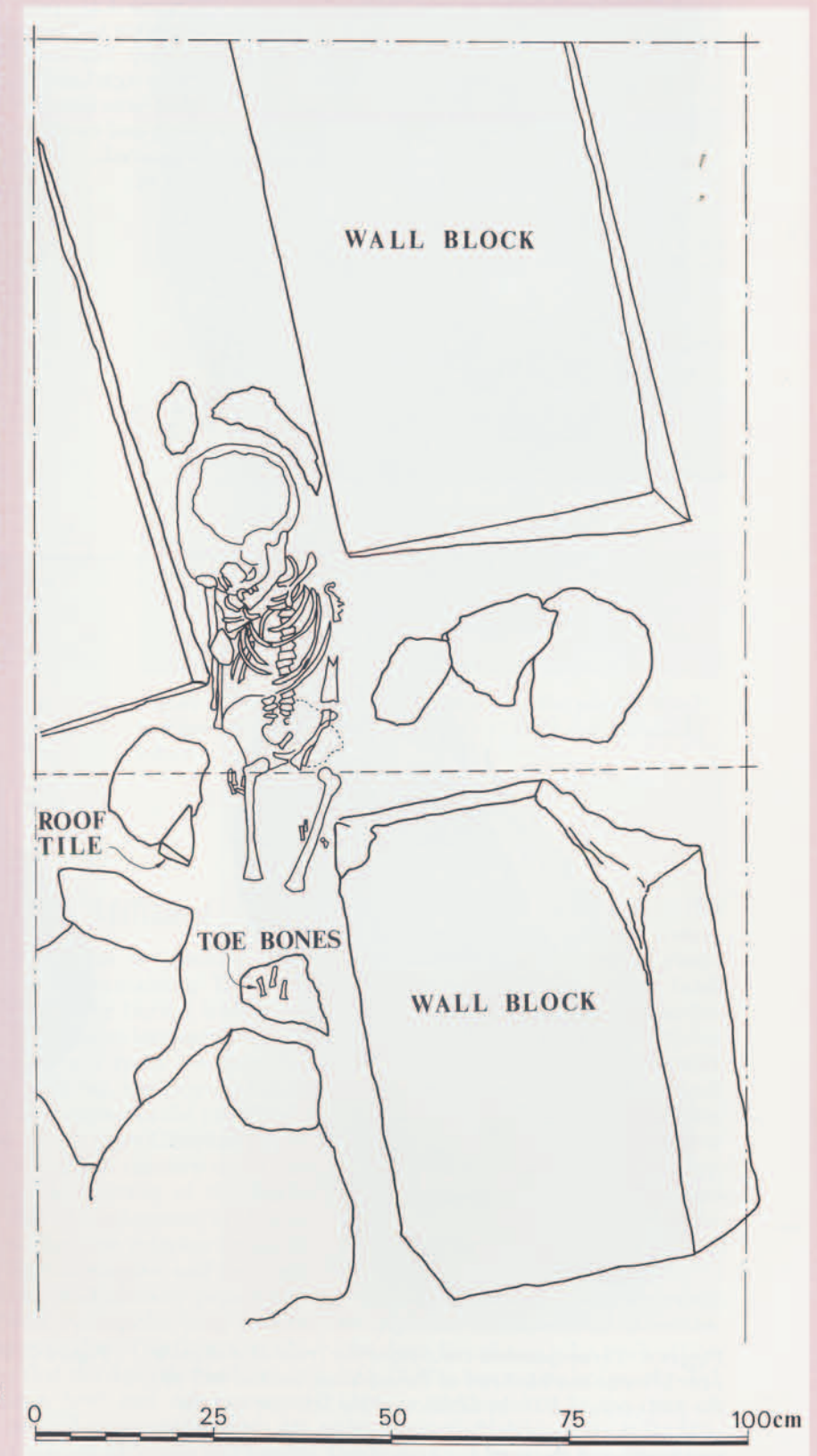


Figure 4. Drawing of the skeleton by its excavator, the 1978 season's staff conservator, Gayle Wever.